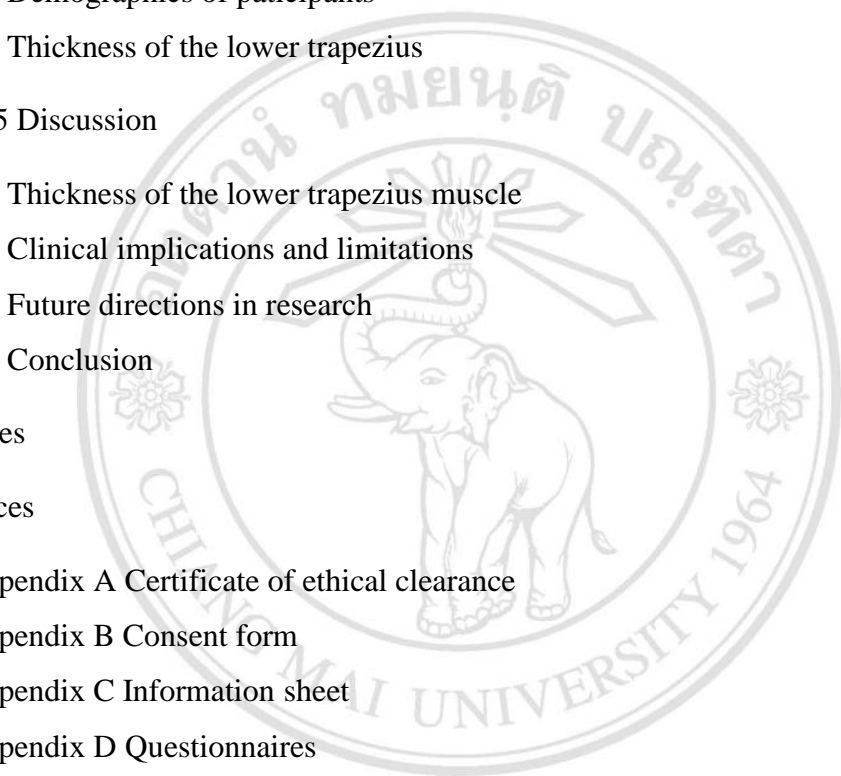


# CONTENTS

	Page
Acknowledgement	d
Abstract in Thai	e
Abstract in English	f
List of Tables	i
List of Figures	j
List of Abbreviations	k
Chapter 1 Introduction	1
1.1 Rationale	1
1.2 Aims of the study	2
1.3 Hypotheses of the study	3
Chapter 2 Literature review	4
2.1 Definitions of neck pain	4
2.2 Prevalence of neck pain	6
2.3 Contributing factors of neck pain	7
2.4 The role of the axioscapular muscles	7
2.5 Alterations of the trapezius muscle behavior in patients with neck pain	10
2.6 Ultrasound imaging and its validity and reliability for measurement of the lower trapezius	12
2.7 Summary statement	14
Chapter 3 Methods	15
3.1 Sample size calculation	15
3.2 Participants	15
3.3 Measurements	16

3.4 Procedures	18
3.5 Independent and dependent variables	20
3.6 Statistical analysis	21
3.7 Location	21
Chapter 4 Results	22
4.1 Demographics of participants	22
4.2 Thickness of the lower trapezius	23
Chapter 5 Discussion	25
5.1 Thickness of the lower trapezius muscle	25
5.2 Clinical implications and limitations	28
5.3 Future directions in research	29
5.4 Conclusion	29
References	31
Appendices	
Appendix A Certificate of ethical clearance	42
Appendix B Consent form	43
Appendix C Information sheet	45
Appendix D Questionnaires	48
Appendix E Intra-inter rater reliability	55
Curriculum vitae	57



ลิขสิทธิ์มหาวิทยาลัยเชียงใหม่  
 Copyright © by Chiang Mai University  
 All rights reserved

## LIST OF TABLES

	Page
Table 1 Demographic data of participants	22
Table 2 Thickness of the lower trapezius muscle in the neck pain and control groups	24



ลิขสิทธิ์มหาวิทยาลัยเชียงใหม่  
Copyright© by Chiang Mai University  
All rights reserved

## LIST OF FIGURES

	Page
Figure 1 The anatomic region of the neck from the back and the side	5
Figure 2 Lower trapezius muscle and serratus anterior muscle	8
Figure 3 Force couple of the upper trapezius, lower trapezius and serratus anterior muscles	9
Figure 4 Measurement of the thickness of the lower trapezius muscle	18
Figure 5 The ultrasound imaging measurement of the lower trapezius muscle during contraction at 120° shoulder abduction	19
Figure 6 Flow chart of the study procedure	20

## LIST OF ABBREVIATIONS

% IEMG	Percent integrated electromyography
BMI	Body mass index
cm	Centimeter
EMG	Electromyography
IASP	International association for the study of pain
kg	Kilogram
MHz	Megahertz
mm	Millimeter
MRI	Magnetic resonance imaging
NDI	Neck disability index
NDI-TH	Neck disability index-thai version
RUSI	Rehabilitative ultrasound imaging
VAS	Visual analog scale
WAD	Whiplash-associated disorders
yrs	Years

ลิขสิทธิ์มหาวิทยาลัยเชียงใหม่  
Copyright© by Chiang Mai University  
All rights reserved